Pathology International

Pathology International 2010; **60**: 373–377 doi:10.1111/j.1440-1827.2010.02528.x

Original Article

Histopathologic findings of transbronchial biopsy in usual interstitial pneumonia

Hyo Sup Shim,[1] Moo Suk Park[2] and In Kyu Park[3]

Department of [1]Pathology, [2]Internal Medicine, and [3]Thoracic and Cardiovascular Surgery, Yonsei University College of Medicine, Seoul, Korea

The role of transbronchial biopsy in diagnosis of usual interstitial pneumonia (UIP) is controversial. In this study, we retrospectively reviewed transbronchial biopsy specimens according to the similar criteria of previous studies, and evaluated whether diagnostic findings of UIP could be found in transbronchial biopsies. Thirty two patients with usual interstitial pneumonia, confirmed by surgical lung biopsy, were identified. In three cases (9.4%), there were combinations of interstitial fibrosis and fibroblast foci, and these findings were considered consistent with usual interstitial pneumonia. No patchwork fibrosis or honeycomb change was found. Diagnostic findings of usual interstitial pneumonia were not frequently manifested in transbronchial biopsy specimens in our study (3 out of 32 cases, 9.4%), compared with a previous report (9 out of 22 cases, 41%). In conclusion, it cannot be claimed that transbronchial biopsy is more useful in confirming usual interstitial pneumonia than previously recognized. The primary and main role of transbronchial biopsy in diagnosis of usual interstitial pneumonia is thought not to confirm a diagnosis, but to exclude other infiltrative diseases, such as malignancy, sarcoidosis or infections.

Key words: histopathology, transbronchial biopsy, usual interstitial pneumonia

The role of transbronchial biopsy (TBB) in diagnosis of idiopathic interstitial pneumonias is controversial.[1,2] Overall opinions were that TBBs are 'not helpful' or 'not useful' in the diagnosis of most of the idiopathic interstitial pneumonias.[3] However, there has been an opinion that TBB can be useful in confirming interstitial lung disease, especially usual interstitial pneumonia (UIP). In a retrospective study limited to UIP, forty one percent of TBB specimens showed histologically diagnostic or consistent findings.[2]

From the clinical viewpoint, when patients have interstitial lung disease pattern, TBB is usually performed to rule out infiltrative diseases, such as lymphangitic carcinoma, sarcoidosis, and infectious diseases. A diagnosis of exclusion can be helpful in some clinical settings.[4] In the view of pathologic practice, first and foremost pathologists examine whether diagnostic findings, such as malignancy or granulomas, are present in TBB specimens. When there is no evidence of malignancy or granulomas, they do a descriptive diagnosis about nonspecific features in some cases. Since nonspecific findings, such as interstitial fibrosis or inflammation, are known to be a poor predictor of idiopathic interstitial pneumonias in surgical lung biopsy, pathologists are apt to assume that it is impossible to obtain the diagnostic histopathologic findings from TBB, especially in diagnosis of idiopathic interstitial pneumonias. On the other hand, although the size of the tissue obtained by TBB is small and available information is limited, detailed pathologic descriptions of what UIP might look like in TBBs were provided in the aforementioned report.[2]

In this study, we retrospectively reviewed TBB specimens from patients confirmed as UIP by surgical lung biopsy and diagnosed as idiopathic pulmonary fibrosis by clinical-radiologic-pathologic correlation. Non-UIP interstitial lung diseases were also reviewed in the same way. We evaluated whether diagnostic findings of UIP could be found in TBBs according to the similar method of previous studies.

MATERIALS AND METHODS

Thirty two patients were identified who underwent TBB followed by surgical lung biopsy at Severance Hospital in Seoul, Korea from 2005 to 2008. In all patients, the histologic finding of surgical lung biopsy showed UIP. The histopathologic

Correspondence: Hyo Sup Shim, MD, Department of Pathology, Yonsei University College of Medicine, 250 Seongsanno, Seodaemun-gu, Seoul 120-752, Korea. Email: shimhs@yuhs.ac

Received 9 October 2009. Accepted for publication 23 December 2009.

© 2010 The Authors
Journal compilation © 2010 Japanese Society of Pathology and Blackwell Publishing Asia Pty Ltd

diagnosis of UIP was based on criteria previously described, including a mixture of patchy interstitial fibrosis, fibroblastic foci, and honeycomb change.[3,5]

Hematoxylin-eosin (H&E)-stained slides were reviewed. The number of slides was from 1 to 2 (mean 1.2).

The size of the biopsied pieces was from 1 to 3 mm. The number of pieces of lung parenchyma with alveoli and bronchial wall were counted. The following eight histopathologic findings were evaluated: (1) patchwork fibrosis, (2) fibroblastic foci, (3) honeycomb change, (4) nonspecific interstitial fibrosis, (5) interstitial inflammation, (6) pneumocyte hyperplasia, (7) intra-alveolar macrophage accumulation, (8) intra-alveolar fibroblast plugs. Patchwork fibrosis was characterized by alternating foci of interstitial dense fibrosis and normal lung without intervening transition zones.[6] Fibroblast foci were characterized by small interstitial aggregates of spindle-shaped cells within myxoid stroma.[6] Honeycomb change was characterized by enlarged, restructured airspaces occurring within fibrotic interstitium.[6]

The findings were considered diagnostic of UIP if there was patchwork interstitial fibrosis along with fibroblastic foci or honeycomb change, or both; findings were consistent with UIP if there was interstitial fibrosis lacking a patchwork pattern with either fibroblast foci or honeycomb change; findings were nonspecific if there were other findings except the above findings; findings were normal if pathologic findings were absent; and findings were insufficient if only bronchial wall tissue was present. This criteria is similar to a previously described one.[2]

To compare with TBB findings of non-UIP, we reviewed patients showing clinical and radiological interstitial pneumonia pattern during the same period. Patients confirmed as malignancy, infectious diseases or sarcoidosis were excluded. Twelve patients were identified in whom both TBB and surgical lung biopsy were performed. Hematoxylin-eosin-stained slides of TBB were reviewed according to the same histopathologic criteria. The number of slides was from 1 to 5 (mean 1.8).

RESULTS

There were 21 men and 11 women (age range: 40–73 years, mean: 61.7 years). All patients underwent surgical lung biopsy and were finally diagnosed as idiopathic pulmonary fibrosis by clinical-radiologic-pathologic correlation.

The histopathologic findings of TBBs are shown in Table 1. Twenty seven (84%) were considered adequate, containing at least one fragment of alveolated parenchyma (mean: 2.2, range: 1–5), while there was only bronchial wall tissue in 5 specimens (16%).

Specimens in three cases (9.4%) showed findings considered consistent with UIP. In all three cases (case no. 4, 18, and 26), there was a combination of interstitial fibrosis and fibroblast foci (Figs 1–3). The patchwork pattern was not definite in all biopsied tissues. No honeycomb change was also found.

Twenty patients (62.5%) had interstitial fibrosis or other nonspecific findings. Four patients (12.5%) had no abnormal findings.

Common histopathologic findings of TBBs in patients with UIP were as follows in order (Table 2): intra-alveolar macrophage accumulation (53.1%), nonspecific interstitial fibrosis (46.9%), pneumocyte hyperplasia (46.9%), and interstitial inflammation (18.8%).

Characteristics of twelve patients with non-UIP were as follows: there were 9 men and 3 women (age range: 29–81 years, mean: 59.1 years). All patients underwent surgical biopsy and were finally diagnosed as bronchiolitis obliterans organizing pneumonia (5 cases), respiratory bronchiolitis (3 cases), nonspecific interstitial pneumonia (2 cases), and hypersensitivity pneumonia (2 cases). The most common finding of TBBs was intra-alveolar macrophage accumulation (58.3%). There was no finding of patchwork fibrosis, fibroblast foci, or honeycomb change, which are considered as characteristics for UIP (Table 2).

DISCUSSION

The role of TBB in diagnosis of interstitial lung disease has been discussed. A previous report of the American Thoracic Society/European Respiratory Society described that 'TBBs are not useful in the diagnosis of most of the idiopathic interstitial pneumonias, with exception of diffuse alveolar damage/acute interstitial pneumonia, and occasionally organizing pneumonia/cryptogenic organizing pneumonia. The primary role of TBBs is to exclude sarcoidosis and certain infections.'[3] However, a recent study of Berbescu *et al.* reported that characteristic histologic features of UIP can be identified on TBB specimens more often previously appreciated.[2] In that study, 9 out of 22 cases (41%) showed diagnostic or consistent features for UIP.

In this study, we evaluated histopathologic findings of TBBs according to a similar method. However, diagnostic findings of UIP were not frequently manifested in TBB specimens in our study (3 out of 32 cases, 9.4%), compared with the previous report (9 out of 22 cases, 41%). Although it could be thought that the number of alveolated lung fragments sampled affects these results, there was no significant difference between two studies (mean, 2.2 vs. 2.5).

It has been thought usually that UIP cannot be diagnosed with a TBB specimen, because UIP is a process that involves the periphery of the lung lobule and these areas are not sampled adequately in TBB.[7] The result of this study also showed that diagnostic findings of UIP were not easily

© 2010 The Authors
Journal compilation © 2010 Japanese Society of Pathology and Blackwell Publishing Asia Pty Ltd

14401827, 2010, 5, Downloaded from https://onlinelibrary.wiley.com/doi/10.1111/j.1440-1827.2010.02528.x by Universitatsbibliothek RWTH Aachen University, Wiley Online Library on [06/03/2026]. See the Terms and Conditions (https://onlinelibrary.wiley.com/terms-and-conditions) on Wiley Online Library for rules of use; OA articles are governed by the applicable Creative Commons License

Table 1 Histopathologic findings of transbronchial biopsy in usual interstitial pneumonia patients

Case No.	BW	AP	PF	FF	HC	IF	II	PH	IMA	FP	Interpretation
4	2	4	–	+	–	+	+	+	+	–	C/W UIP
18	4	4	–	+	–	+	+	+	+	–	C/W UIP
26	3	2	–	+	–	+	–	+	–	–	C/W UIP
22	4	3	–	–	–	+	+	+	–	–	Nonspecific
6	2	5	–	–	–	+	+	+	+	+	Nonspecific
5	3	3	–	–	–	+	+	+	+	–	Nonspecific
8	1	5	–	–	–	+	+	+	+	–	Nonspecific
14	5	1	–	–	–	+	–	+	+	+	Nonspecific
7	3	2	–	–	–	+	–	+	+	–	Nonspecific
27	3	2	–	–	–	+	–	+	+	–	Nonspecific
12	5	2	–	–	–	+	–	+	+	–	Nonspecific
21	3	3	–	–	–	+	–	+	–	–	Nonspecific
13	9	1	–	–	–	+	–	+	–	–	Nonspecific
9	8	1	–	–	–	+	–	–	–	–	Nonspecific
10	4	2	–	–	–	+	–	–	–	–	Nonspecific
3	3	1	–	–	–	–	–	+	+	–	Nonspecific
25	5	1	–	–	–	–	–	+	+	–	Nonspecific
2	8	2	–	–	–	–	–	–	+	–	Nonspecific
11	4	3	–	–	–	–	–	–	+	–	Nonspecific
15	5	2	–	–	–	–	–	–	+	–	Nonspecific
19	4	1	–	–	–	–	–	–	+	–	Nonspecific
23	6	1	–	–	–	–	–	–	+	–	Nonspecific
30	4	4	–	–	–	–	–	–	+	–	Nonspecific
20	4	1	–	–	–	–	–	–	–	–	Normal
29	5	1	–	–	–	–	–	–	–	–	Normal
31	4	1	–	–	–	–	–	–	–	–	Normal
32	4	2	–	–	–	–	–	–	–	–	Normal
1	8	0	–	–	–	–	–	–	–	–	Insufficient
16	7	0	–	–	–	–	–	–	–	–	Insufficient
17	8	0	–	–	–	–	–	–	–	–	Insufficient
24	6	0	–	–	–	–	–	–	–	–	Insufficient
28	5	0	–	–	–	–	–	–	–	–	Insufficient

BW, No. of Pieces of Bronchial wall; AP, No. of Pieces of Alveolated parenchyma; PF, patchwork fibrosis; FF, fibroblastic foci; HC, honeycomb change; IF, nonspecific interstitial fibrosis; II, interstitial inflammation; PH, pneumocyte hyperplasia; IMA, intra-alveolar macrophage accumulation; FP, intra-alveolar fibroblast plugs; C/W, consistent with; +, present; –, absent.

Table 2 Frequencies of histopathologic findings of transbronchial biopsies

	UIP (n = 32)		Non-UIP (n = 12)	
Histopathologic findings	Number	Percentage	Number	Percentage
Intraalveolar macrophage accumulation	17	53.1%	7	58.3%
Nonspecific interstitial fibrosis	15	46.9%	0	0.0%
Pneumocyte hyperplasia	15	46.9%	6	50.0%
Interstitial inflammation	6	18.8%	5	41.7%
Fibroblast foci	3	9.4%	0	0.0%
Fibroblast plugs	2	6.3%	4	33.3%
Patchwork fibrosis	0	0.0%	0	0.0%
Honeycomb change	0	0.0%	0	0.0%

UIP, usual interstitial pneumonia.

sampled by TBB. For example, in our study, there was no definite patchwork fibrosis in TBB. Patchwork fibrosis is one of the most important findings of UIP. Patchwork pattern fibrosis is generally recognized in the low power view of a surgical lung biopsy specimen. One of limitations of TBB is that it is impossible to evaluate the various lesions in low power view, because the biopsied tissue is fragmented and measures about 1–3 mm. One report emphasized that shirt-sleeve magnification or low power magnification serves as useful adjuncts in the general categorization of noninfectious medical lung disease.[8] It shows that low power pattern is of as much importance in diagnosis of interstitial lung disease. Also, honeycomb change was not found in our study, which first begins in basal peripheral lung fields. It seems that

© 2010 The Authors
Journal compilation © 2010 Japanese Society of Pathology and Blackwell Publishing Asia Pty Ltd

14401827, 2010, 5, Downloaded from https://onlinelibrary.wiley.com/doi/10.1111/j.1440-1827.2010.02528.x by Universitatsbibliothek RWTH Aachen University, Wiley Online Library on [06/03/2026]. See the Terms and Conditions (https://onlinelibrary.wiley.com/terms-and-conditions) on Wiley Online Library for rules of use; OA articles are governed by the applicable Creative Commons License

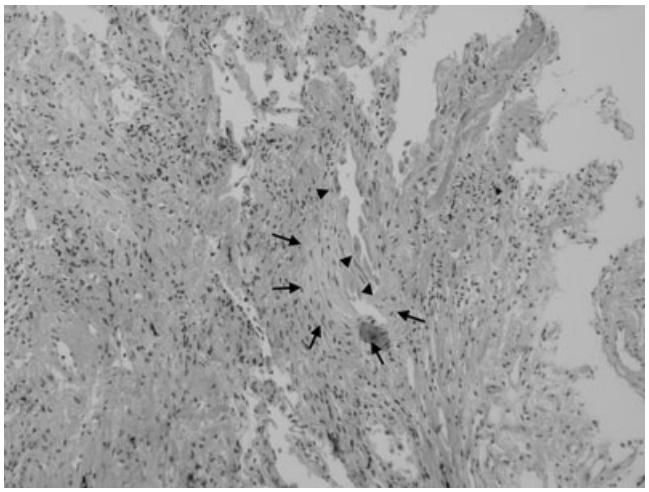

Figure 1 Case 4. There is fibroblast focus (arrow) with surrounding interstitial fibrosis. Lining of type II pneumocytes (arrowhead) is recognized (Hematoxylin-Eosin stain).

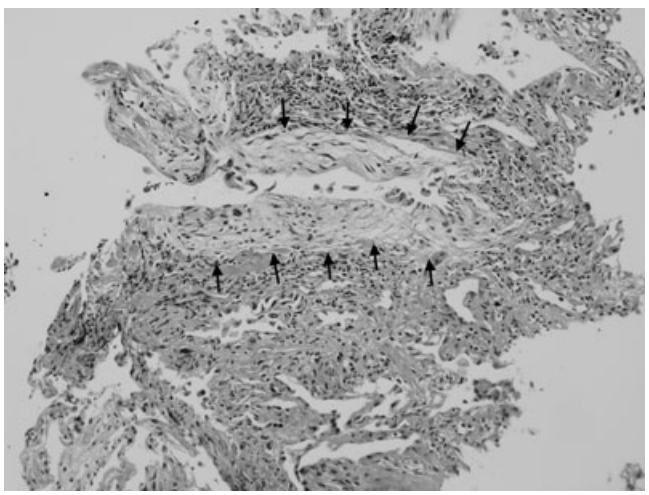

Figure 2 Case 18. Myxoid character of fibroblast foci (arrow) is manifest in this photograph (Hematoxylin-Eosin stain).

extent of UIP, whether the lesion is mainly located peripherally or extends to central area, affects histopathologic findings of TBB specimens.

Another reason to make a diagnosis of UIP difficult is parenchymal collapse induced by TBB. The collapse can obscure the proper evaluation of alveolar architecture. It may deform not only diagnostic findings of UIP, but also normal lung architecture. Since a collapsed lung may sometimes mimic interstitial lung disease, careful attention is necessary. A differential point is that type II pneumocyte hyperplasia is accompanied by most of interstitial fibrosis. In the histopathologic findings of TBB in our study, 13 out of 15 cases (86.7%) with interstitial fibrosis accompanied pneumocyte hyperplasia. Recognition of pneumocyte hyperplasia in obscure cases helps confirm interstitial fibrosis rather than atelectasis.[2]

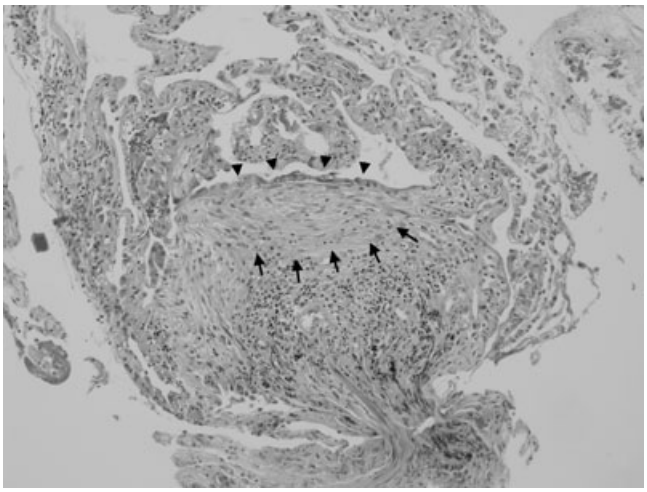

Figure 3 Case 26. This lesion (arrow) is characterized by fibroblasts arranged parallel to the alveolar lining (arrowhead) in myxoid background (Hematoxylin-Eosin stain).

A unique aspect of our study is that the TBB findings of UIP were compared with those of non-UIP. Although the case number of non-UIP was small, there were some differences between two groups. In the non-UIP group, there was no interstitial fibrosis or fibroblast foci. According to the previous criteria,[2] we classified interstitial fibrosis lacking patchwork pattern with fibroblast foci as consistent finding of UIP. Most of the UIP-like histological features tend to be somewhat non-specific. For example, it is now recognized that fibroblast foci occur in other interstitial lung disease. Only one finding is insufficient for diagnosis, however, combination of pathologic findings, such as interstitial fibrosis and fibroblast foci, can be considered consistent with UIP. We think that TBB cannot be ultimately the alternate of the surgical lung biopsy. However, there is a situation that TBB is necessary and useful. It can aid the diagnosis of elderly patients or generally weak patients who cannot undergo surgical lung biopsy. Among three TBB cases consistent with UIP in our study, two cases were radiologically consistent with UIP. One case showed atypical radiological finding. If surgical lung biopsy cannot be performed, we think that the former two cases can be diagnosed as idiopathic pulmonary fibrosis, however, the latter case should be carefully diagnosed. So, meticulous clinical-radiologic-pathologic correlation should follow for proper management.

The limitation of this study is that there could be a selection bias lying between the patients who underwent surgical lung biopsy with or without prior TBB. In our institution, of course, not all patients have TBB performed. When the other diseases cannot be completely excluded in radiological findings (for example, ground glass opacity, nodular lesions, infectious diseases), TBB is performed first of all to rule out these diseases. Since high resolution computed tomography has an important diagnostic role in idiopathic interstitial

© 2010 The Authors
Journal compilation © 2010 Japanese Society of Pathology and Blackwell Publishing Asia Pty Ltd

14401827, 2010, 5, Downloaded from https://onlinelibrary.wiley.com/doi/10.1111/j.1440-1827.2010.02528.x by Universitatsbibliothek RWTH Aachen University, Wiley Online Library on [06/03/2026]. See the Terms and Conditions (https://onlinelibrary.wiley.com/terms-and-conditions) on Wiley Online Library for rules of use; OA articles are governed by the applicable Creative Commons License

pneumonia, lung biopsy is increasingly limited to those patients with atypical radiological findings. This may mean that there is a growing selection bias toward lung biopsy cases. However, in this situation, several reports showed that pathologic diagnosis of UIP remains the single most important predictor of outcome at the time of diagnosis.[9–11]

In conclusion, diagnostic findings for UIP were not frequently found in TBB specimen. The primary and main role of TBB in diagnosis of UIP is thought not to confirm a diagnosis, but to exclude other infiltrative diseases, such as malignancy, sarcoidosis or infections.

REFERENCES

1 Churg A, Schwarz M. Transbronchial biopsy and usual interstitial pneumonia: A new paradigm? *Chest* 2006; **129**: 1117–8.
2 Berbescu EA, Katzenstein AL, Snow JL, Zisman DA. Transbronchial biopsy in usual interstitial pneumonia. *Chest* 2006; **129**: 1126–31.
3 American Thoracic Society/European Respiratory Society International Multidisciplinary Consensus Classification of the Idiopathic Interstitial Pneumonias. This joint statement of the American Thoracic Society (ATS), and the European Respiratory Society (ERS) was adopted by the ATS board of directors, June 2001 and by the ERS Executive Committee, June 2001. *Am J Respir Crit Care Med* 2002; **165**: 277–304.
4 Ensminger SA, Prakash UB. Is bronchoscopic lung biopsy helpful in the management of patients with diffuse lung disease? *Eur Respir J* 2006; **28**: 1081–4.
5 Travis WD, Matsui K, Moss J, Ferrans VJ. Idiopathic nonspecific interstitial pneumonia: Prognostic significance of cellular and fibrosing patterns: Survival comparison with usual interstitial pneumonia and desquamative interstitial pneumonia. *Am J Surg Pathol* 2000; **24**: 19–33.
6 Katzenstein A, Zisman DA, Litzky LA, Nguyen BT, Kotloff RM. Usual interstitial pneumonia: Histologic study of biopsy and explant specimens. *Am J Surg Pathol* 2002; **26**: 1567–77.
7 Leslie KO, Wick MR. *Practical Pulmonary Pathology: A Diagnostic Approach*. Philadelphia, PA: Churchill Livingstone, 2005.
8 Mark EJ, Ruangchira-Urai R, Kradin RL. Shirt-sleeve or scanning magnification as an aid to the diagnosis of commonly encountered medical lung diseases. *Arch Pathol Lab Med* 2008; **132**: 539–47.
9 Flaherty KR, Thwaite EL, Kazerooni EA *et al.* Radiological versus histological diagnosis in UIP and NSIP: Survival implications. *Thorax* 2003; **58**: 143–8.
10 Sumikawa H, Johkoh T, Colby TV *et al.* Computed tomography findings in pathological usual interstitial pneumonia: Relationship to survival. *Am J Respir Crit Care Med* 2008; **177**: 433–9.
11 Myers JL, Katzenstein AL. Beyond a consensus classification for idiopathic interstitial pneumonias: Progress and controversies. *Histopathology* 2009; **54**: 90–103.

© 2010 The Authors
Journal compilation © 2010 Japanese Society of Pathology and Blackwell Publishing Asia Pty Ltd

14401827, 2010, 5, Downloaded from https://onlinelibrary.wiley.com/doi/10.1111/j.1440-1827.2010.02528.x by Universitatsbibliothek RWTH Aachen University, Wiley Online Library on [06/03/2026]. See the Terms and Conditions (https://onlinelibrary.wiley.com/terms-and-conditions) on Wiley Online Library for rules of use; OA articles are governed by the applicable Creative Commons License